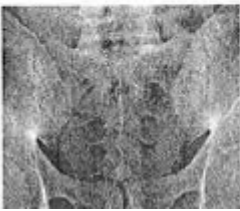


Sacrum/Coccyx X-ray Guideline

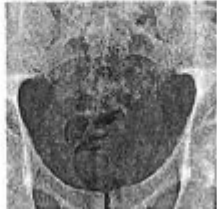Routine: 3 views

- AP SACRUM with central ray angled 15 degrees cephalad
- AP COCCYX with central ray angled 10 degrees caudad
- LATERAL Sacrum/Coccyx

SACRUM



COCCYX



LATERAL

