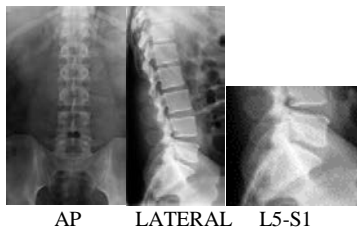


Lumbar Spine X-ray Guideline

Note: For initial evaluation after trauma, routine 3 view (AP/Lateral/L5-S1 Spot) is recommended unless requested by a spine surgeon.

Routine: 3 views

- AP
- LATERAL (AP and LAT views should be centered on L3, and use proper collimation)
- L5-S1 SPOT (centered and coned to L5-S1 level with beam straight through disc)
Please label if performed upright or supine.



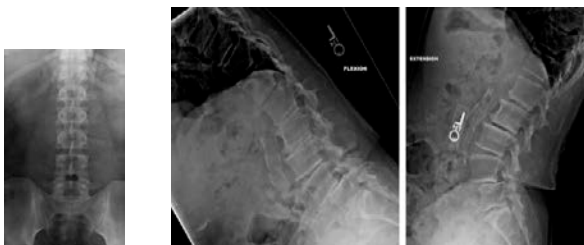Surgical/Neurosurgeon follow-up: 2 or 3 views

- Post-op – **Center on hardware.**
- AP
- LATERAL Centered at hardware (if hardware is L4-L5-S1, “normal lateral” and lateral spot centered at hardware)
- AP Spot/Sacral view (if requested) - do AP with 30 deg. Cephalad for L5-S1 spot.

Special views: Obtain only if requested (Flex/Extension may be done as individual exam see below)

Note: When a 7 view L-spine is requested, please consult with Radiologist unless ordered by a spine surgeon.

- OBLIQUES
- AP, FLEXION AND EXTENSION (3 VIEW IF PATIENT DOES NOT HAVE COMPARISONS)
- FLEXION AND EXTENSION (2 VIEW IF PATIENT HAS COMPARISONS)



AP

FLEXION

EXTENSION

Reviewed 2016 AMR