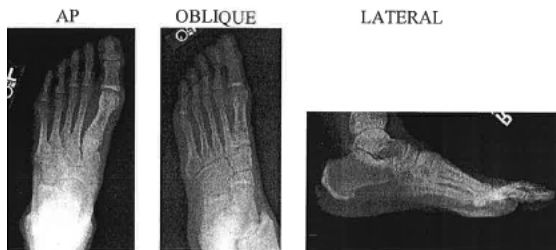


Foot X-ray Guideline

Routine: 3 views

- Standard AP - CR angled 10 degrees toward heel
- OBLIQUE – 30-40 degree medial oblique
- LATERAL
- Weight-bearing
 - AP, OBLIQUE, and LATERAL (if requested)



Foreign body: 2 views

- Standard AP and LATERAL
- Mark entrance site or region of interest with BB skin marker or radiopaque arrow/marker on the image. Please document that these markers are being utilized. Please do not place PACS markers on the image.

Arthritis: 3 views

- AP, OBLIQUE, and LATERAL

Evaluation of Congenital Anomaly (Newborn or older child) (Clubfoot)

- AP and LATERAL weight-bearing
- For infants who cannot weight bear
 - AP – Obtained with the leg vertical and perpendicular to the imaging plane
 - LATERAL - A Plexiglas (or other radiolucent surface) should be pressed against the foot for LATERAL view, which should be obtained in maximal dorsiflexion.
- Align CR with the ankle, not the foot. Show to MSK radiologist