

Reference for US Thyroid Nodule

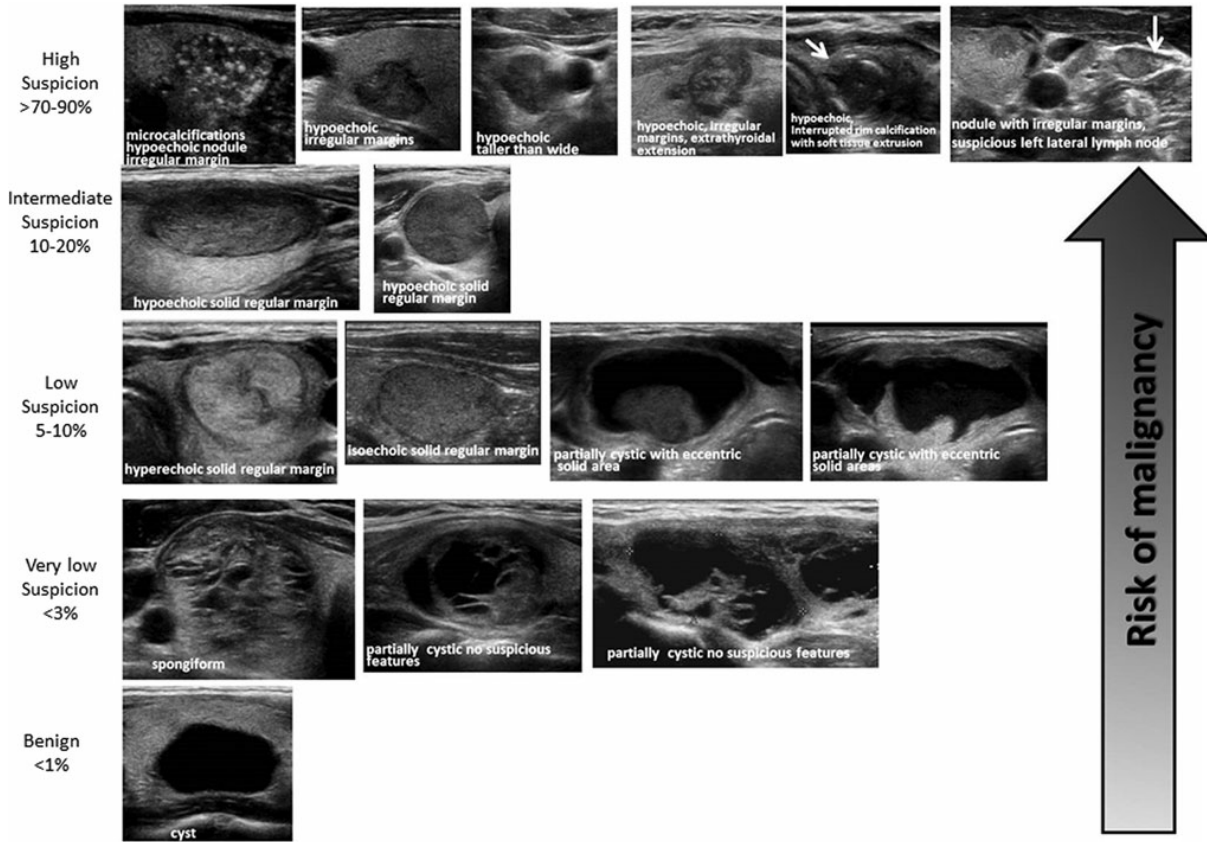


FIG. 2. ATA nodule sonographic patterns and risk of malignancy.

TABLE 6. SONOGRAPHIC PATTERNS, ESTIMATED RISK OF MALIGNANCY, AND FINE-NEEDLE ASPIRATION GUIDANCE FOR THYROID NODULES

Sonographic pattern	US features	Estimated risk of malignancy, %	FNA size cutoff (largest dimension)
High suspicion	Solid hypoechoic nodule or solid hypoechoic component of a partially cystic nodule with one or more of the following features: irregular margins (infiltrative, microlobulated), microcalcifications, taller than wide shape, rim calcifications with small extrusive soft tissue component, evidence of ETE	>70–90 ^a	Recommend FNA at ≥ 1 cm
Intermediate suspicion	Hypoechoic solid nodule with smooth margins without microcalcifications, ETE, or taller than wide shape	10–20	Recommend FNA at ≥ 1 cm
Low suspicion	Isoechoic or hyperechoic solid nodule, or partially cystic nodule with eccentric solid areas, without microcalcification, irregular margin or ETE, or taller than wide shape.	5–10	Recommend FNA at ≥ 1.5 cm
Very low suspicion	Spongiform or partially cystic nodules without any of the sonographic features described in low, intermediate, or high suspicion patterns	<3	Consider FNA at ≥ 2 cm Observation without FNA is also a reasonable option
Benign	Purely cystic nodules (no solid component)	<1	No biopsy ^b

US-guided FNA is recommended for cervical lymph nodes that are sonographically suspicious for thyroid cancer (see Table 7).

^aThe estimate is derived from high volume centers, the overall risk of malignancy may be lower given the interobserver variability in sonography.

^bAspiration of the cyst may be considered for symptomatic or cosmetic drainage.

ETE, extrathyroidal extension.