

CT MSK Wrist Guideline



Indications: Pain, injury, known fracture

Oral Contrast: None

IV Contrast: None


PLEASE NOTE:

If the wrist is obliqued on the scanner table, axial reconstructions need to be angled perpendicular to the wrist joint and reformations need to be angled parallel to the long axis of the radius so as to yield TRUE orthogonal planes.

**SEE SECOND PAGE for examples of all 3 orthogonal planes
(4th example is for navicular/scaphoid reformations)**

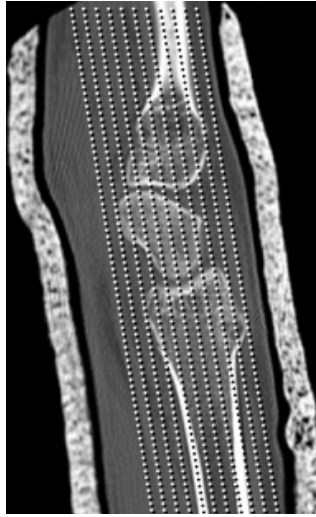
Positioning	Prone, Arm over head
FOV	Patient Size (small FOV)
Axial Reconstruction: Thickness/ Interval/ Algorithm	(1) 3mm/3mm/Sharp Use TRUE Coronal (2) 3mm/3mm/Soft
Start Location	Lower 1/3 of the metacarpals
End Location	2-3cm below distal radioulnar joint
Gantry Angle	None
Reformations: Thickness/ Interval/ Algorithm	(1) Coronal (use TRUE Sagittal) 2mm/2mm/Sharp (2) Sagittal (use TRUE Sagittal) 3mm/3mm/Sharp (3) OPTIONAL: For SCAPHOID or NAVICULAR Oblique Sagittal (Use TRUE Coronal) 1mm/1mm/Sharp
Phase of Respiration	None

AXIAL
RECONSTRUCTION:



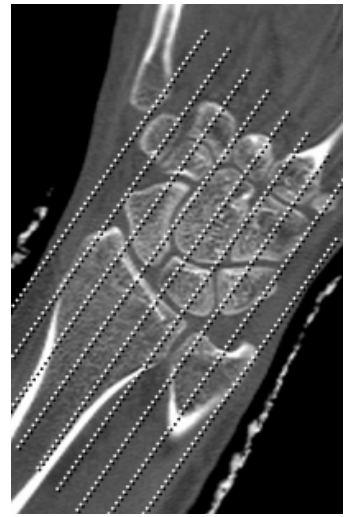
3mm x 3mm

CORONAL
REFORMATION:



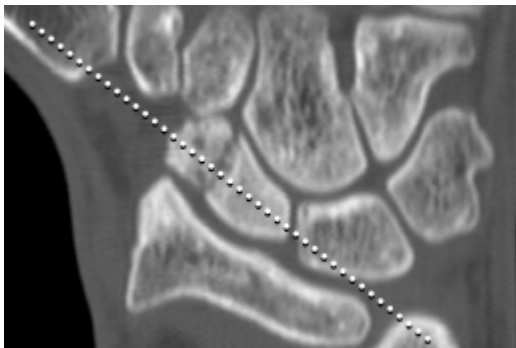
2mm x 2mm

SAGITTAL
REFORMATION:



3mm x 3mm

OBLIQUE SAGITTAL: For Scaphoid/Navicular indication
Angle along the long axis of the scaphoid/navicular (shown below)



1mm x 1mm